

LETTER TO THE EDITOR

Slim exquisite easy-exposing video laryngoscope: A novel video laryngoscope

Chenglong Zhu, Zui Zou

School of Anesthesiology, Naval Medical University, Shanghai 200433, China.

Corresponding author: Zui Zou.**Address correspondence to: Zui Zou**, School of Anesthesiology, Naval Medical University, 800 Xiangyin Road, Yangpu District, Shanghai 200433, China.

E-mail: zouzui@smmu.edu.cn.

Received February 16, 2026; Accepted March 16, 2026; Published March 31, 2026

DOI: 10.61189/551629zyhfv

With the evolution of traditional direct laryngoscopes into video-assisted laryngoscopes, the viewing angle provided by video laryngoscopes has been substantially enlarged, enabling more intuitive and clearer visualization of pharyngeal structures and the glottis. However, the design of video laryngoscopes generally retains the relatively bulky blade carrier of traditional direct laryngoscopes. During routine use, this design may still limit the field of view, necessitating significant jaw elevation to obtain a clear view [1, 2]. To address this limitation, our team developed a slim exquisite easy-exposing video laryngoscope (SEE-VL), a slender and refined device designed to facilitate easier glottic visualization (Registration Certificate No.: Su Xie Zhun 20252082044).

The most significant difference between SEE-VL and traditional video laryngoscopes (e.g., UESCOPE® video laryngoscope) lies in the optimized cross-sectional design of blade carrier. While ensuring adequate exposure of the laryngeal structures, SEE-VL minimizes additional trauma to the oral cavity and larynx, providing more intraoral space for establishing an artificial airway. Additionally, SEE-VL is equipped with a high-resolution display, enabling clearer visualization of the laryngeal structures and glottis (**Figure 1**).

Beyond routine airway establishment, the slim blade design of SEE-VL is particularly suitable for patients with anticipated difficult airways, including those with limited mouth opening, restricted head and neck mobility, or missing teeth—conditions commonly observed in patients with maxillofacial trauma, temporomandibular joint disorders, cervical spine surgery, or obesity). This novel SEE-LV may broaden the clinical applicability of video laryngoscopy in challenging airway scenarios.

DECLARATIONS**Author contributions**

Zui Zou conceived the study, and Chenglong Zhu draft the manuscript.

Funding

This research received no external funding.

Data availability

Not applicable.

Ethics approval and consent to participate

Not applicable.

Consent for publication

Not applicable.

Competing interests

The authors declare that they have no competing interests.

Acknowledgements

Not applicable.

© The Author(s) 2026. Open Access This article is licensed under a Creative Commons Attribution 4.0 International License, which permits use, sharing, adaptation, distribution and reproduction in any medium or format, as long as you give appropriate credit to the original author(s) and the source, provide a link to the Creative Commons licence, and indicate if changes were made. The images or other third party material in this article are included in the article's Creative Commons licence, unless indicated otherwise in a credit line to the material. If material is not included in the article's Creative Commons licence and your intended use is not permitted by statutory regulation or exceeds the permitted use, you will need to obtain permission directly from the copyright holder. To view a copy of this licence, visit <http://creativecommons.org/licenses/by/4.0/>.

View Online



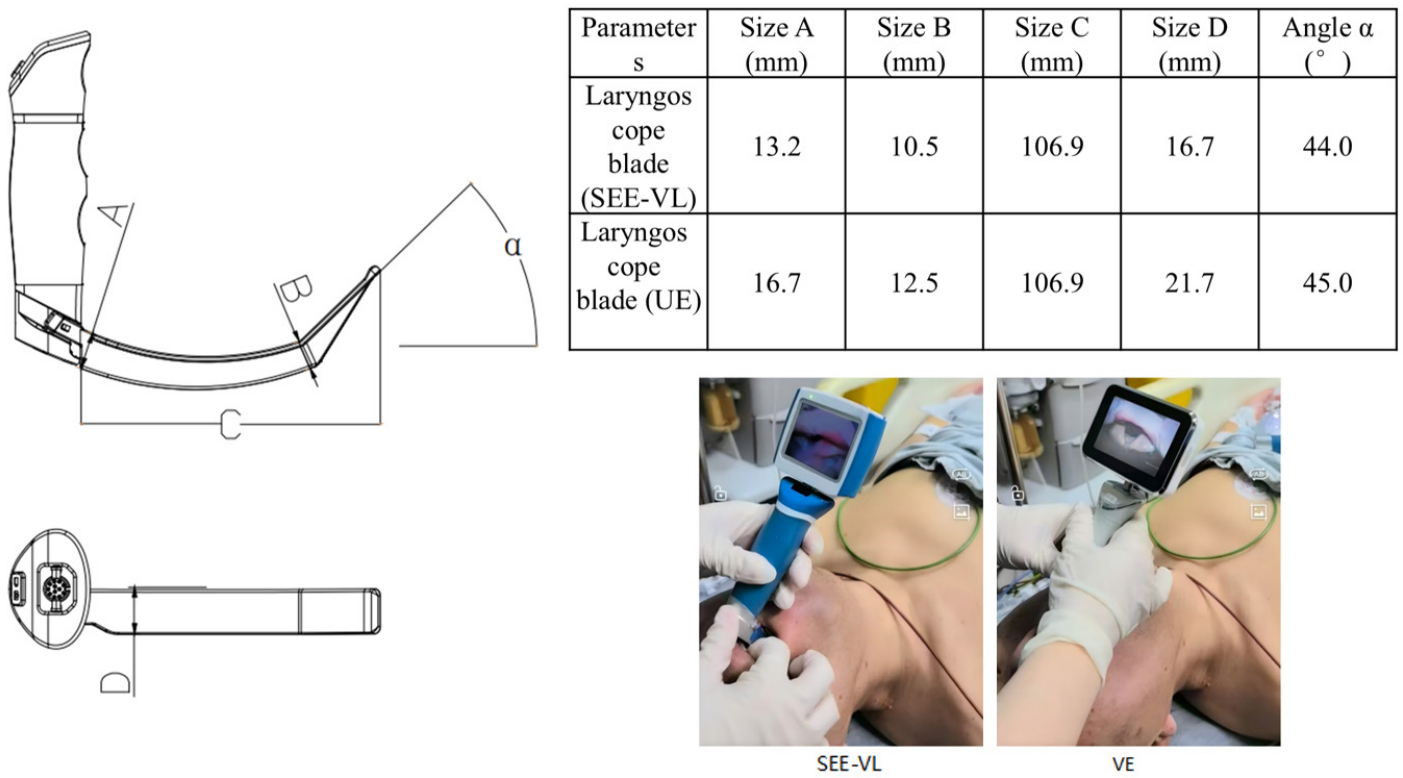


Figure 1. Schematic diagram of the blade carrier in the SEE-VL and its comparison with a conventional video laryngoscope (UESCOPE® video laryngoscope). SEE-VL, Slim Exquisite Easy-exposing Video Laryngoscope.

REFERENCES

[1] Sulser S, Ubmann D, Schlaepfer M, Brucech M, Goliash G, Seifert B, et al. C-MAC videolaryngoscope compared with direct laryngoscopy for rapid sequence intubation in an emergency department: A randomised clinical trial. *Eur J Anaesthesiol.* 2016 Dec;33(12):943-948. <https://doi.org/10.1097/eja.0000000000000525>

[2] Mazzinari G, Rovira L, Henao L, Ortega J, Casasempere A, Fernandez Y, et al. Effect of dynamic versus stylet-guided intubation on first-attempt success in difficult airways undergoing glidescope laryngoscopy: A randomized controlled trial. *Anesth Analg.* 2019 Jun;128(6):1264-1271. <https://doi.org/10.1213/ane.00000000000004102>